



**PATIENT**

Sundaw Stewart

**SPECIES**

Feline

**BREED**

DSH

**SEX**

Female Spayed

**AGE**

12 years

**WEIGHT**

10.3lbs

**INTERPRETED BY**

Maggie Machen Lamy,  
 DVM DACVIM  
 (Cardiology)

**IMAGING PERFORMED BY**

Kelly Reschny, RVT

**HOSPITAL NAME**

Leo Vets

**REFERRING VET**

Dr. Boven

**INVOICE**

47693

**DATE**

4/27/26

**PRESENTING CLINICAL SIGNS**

History: Grade 3/6 heart murmur. Controlled hyperthyroidism; managed on Felimazole 2.5mg PO q24h. Seizure disorder controlled with gabapentin 100 mg PO BID (no recent seizures). Chronic Asthma with recent exacerbation. Chronic left ocular disease.

**ELECTROCARDIOGRAPHIC FINDINGS**

A six lead ECG is available at 25mm/s; 10mm/mV. The ventricular rate is 120bpm with a regular rhythm. P waves can be seen independent of the QRS complexes. The P wave/sinus rate is 188bpm. No premature beats, pauses or other dysrhythmias observed.  
 ECG diagnosis: Complete-3<sup>rd</sup> degree AV block with a junctional escape rhythm.

**ECHOCARDIOGRAM FINDINGS**

2D, m-mode, color flow and doppler imaging is available. The left ventricular walls are mildly irregular yet normal in dimension. There is a diffusely hyperechoic endocardium consistent with fibrosis. The papillary muscles are mildly remodeled and hyperechoic. The endocardium also appears remodeled. The LV is mildly dilated with adequate function. The left atrium is mild to moderately enlarged. The right atrium is normal in size. The right ventricle appears normal. The mitral valve is normal in structure and mobility. Trace MR. No TR. Blood flow through both the LVOT and RVOT is normal in velocity. No pleural or pericardial effusion seen. No obvious cardiac tumors.

**CARDIAC CHART**

FELINE CARDIAC PARAMETERS	BODY WEIGHT (kg)	HR (BPM)	IVSd (cm) <small>(Moise, Pipers)</small>	LVIDd (cm) <small>(Moise, Pipers)</small>	LVWd (cm) <small>(Moise, Pipers)</small>	FS (%)	EF (%)
<b>NORMAL PARAMETER</b>	-----	150-240	0.35-0.55	<2 (mean 1.5)	3.5-0.55	35-67	80-100
<b>PATIENT</b>	4.7	80	0.45	1.8	0.49	54	87
FELINE CARDIAC PARAMETERS	LA/AO <small>(Boon)</small>	LA/AO HEART BASE <small>(Swe) (Abbott)</small>	LA 2D short axis Base view (cm) <small>(Abbott)</small>		LVOT VEL  (m/s)	RVOT VEL  (m/s)	E max  (m/s)
<b>NORMAL</b>	<1.5	<1.3	<1.2		<1.6	<1.3	<0.9
<b>PATIENT</b>	1.5	1.6	1.6		0.8	1.0	NM

*\*Note: All measurements based upon multi-modal images and methods. An average value is reported.*  
 Adapted from June Boon, Veterinary Echocardiography, 1998  
 Abbott J & MacLean H JVIM 2006;20: 111-119, Moise et al. Am J Vet Res 47:1476, 1986. Pipers et al. Am J Vet Res 40:882, 1979.

**INTERPRETATION OF THE FINDINGS & FURTHER RECOMMENDATIONS**

The primary abnormality identified is mild to moderate LA and LV dilation. An early form or unclassified or restrictive disease is possible; however, this can develop simply secondary to chronic bradycardia. The latter is suspected in this case. No significant valve regurgitation is noted, and no additional issues are identified.



**PATIENT**

Sundaw Stewart

**SPECIES**

Feline

**BREED**

DSH

**SEX**

Female Spayed

**AGE**

12 years

**WEIGHT**

10.3lbs

**INTERPRETED BY**

Maggie Machen Lamy,  
 DVM DACVIM  
 (Cardiology)

**IMAGING PERFORMED BY**

Kelly Reschny, RVT

**HOSPITAL NAME**

Leo Vets

**REFERRING VET**

Dr. Boven

**INVOICE**

47693

**DATE**

4/27/26

The ECG is consistent with third degree (or complete) AV block. An escape rhythm is present, with a HR of 120bpm. While AV block is considered a progressive arrhythmic disease, many cats will remain asymptomatic for potentially months to years given adequate cardiac output with this heart rate. Should the escape rhythm deteriorate, however, progressive bradycardia will be noted with concurrent issues such as collapse or lethargy. An epicardial pacemaker becomes necessary in this scenario, in order to maintain QOL going forward with euthanasia as an alternative option. Continued monitoring is advised; however, no treatment for the arrhythmia is indicated at this time. Sudden death is a clear possibility with arrhythmic cats, and this should be expressed to the owner.

Given the totality of the findings, there are 2 ways to go forward at this time in this geriatric cat. First would be to leave well enough alone given an asymptomatic status, pending the results of further systemic evaluation. The second option would be to institute Plavix due to a mild increased risk for blood clot formation. A third option in this case would be to consider referral to a local Cardiologist given the complexity of the findings and potential need for surgery in the future. Discussion with the owner is advised.

Monitor at home for any respiratory issues or signs of blood clot events (neurologic change, paralysis, etc.).

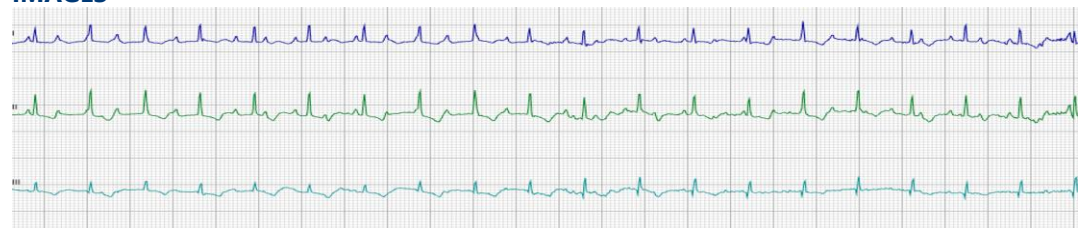Anesthetic risk is considered high and is not advised. If needed, extreme caution must be used for any IV fluid or steroid therapy. Prognosis is guarded to poor long term, however prior to clinical signs many cats can remain stable for some time.

**PLAN**

A screening BP and T4 are recommended every 6 months. If medications are elected to help prolong asymptomatic life, administer as follows: Institute 75mg tabs; Give ¼ tab by mouth every 24 hours (NOTE: bitter along cut edge, may cause foaming at the mouth; coat in entirety).

Consider referral as discussed, pending results of systemic evaluation. Immediate reevaluation of the arrhythmia is advised should the patient experience any acute lethargy or collapse. If the patient does well, reassessment of the rhythm and echocardiogram is recommended in 6 months.

**IMAGES**





**PATIENT**

Sundaw Stewart

**SPECIES**

Feline

**BREED**

DSH

**SEX**

Female Spayed

**AGE**

12 years

**WEIGHT**

10.3lbs

**INTERPRETED BY**

Maggie Machen Lamy,  
DVM DACVIM  
(Cardiology)

**IMAGING PERFORMED BY**

Kelly Reschny, RVT

**HOSPITAL NAME**

Leo Vets

**REFERRING VET**

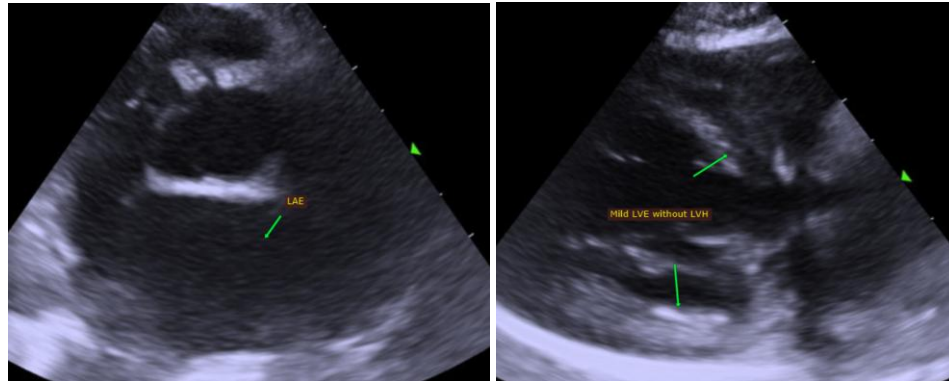
Dr. Boven

**INVOICE**

47693

**DATE**

4/27/26



The information and recommendations provided are based on the images presented by the referring veterinarian. No evaluation can be communicated regarding pathology that was not visible in the image/video clips provided.

Thank you for this referral. This report was generated using transcription software, and minor dictation errors may be present. If the clinical or image interpretation does not parallel your findings or if I can be of any further assistance, please contact me.

**Maggie Machen Lamy, DVM**  
**Diplomate of the American College of Veterinary Internal Medicine (Cardiology)**  
info@sonopath.com